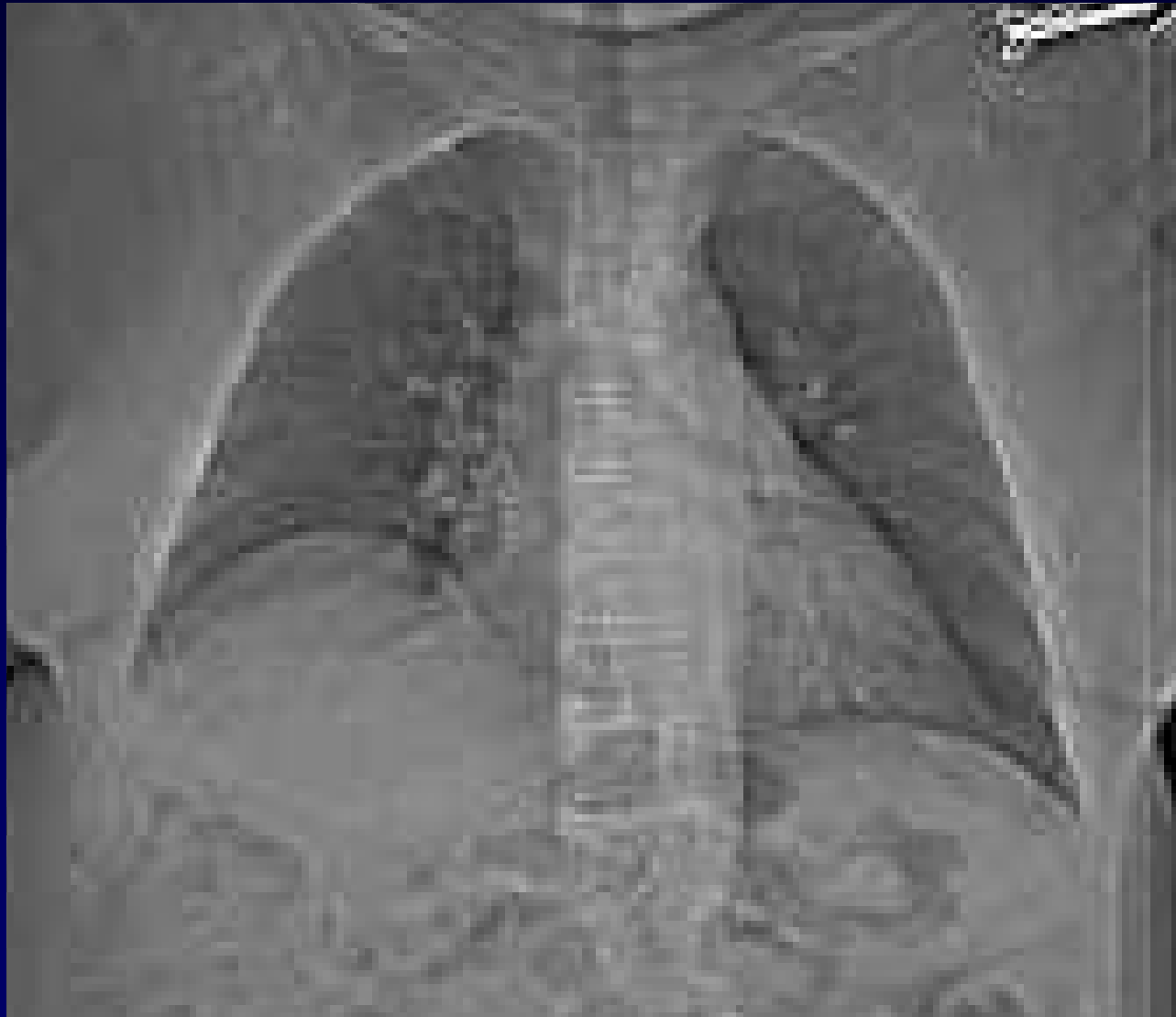

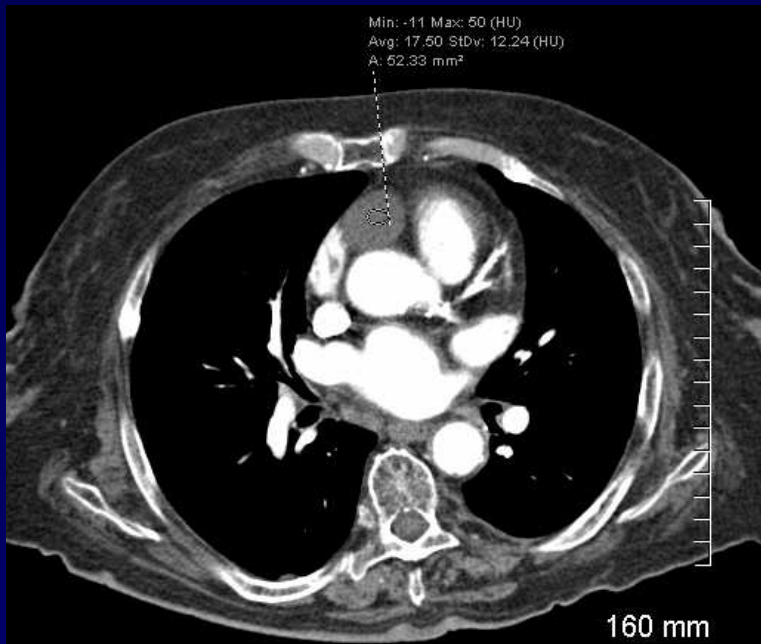
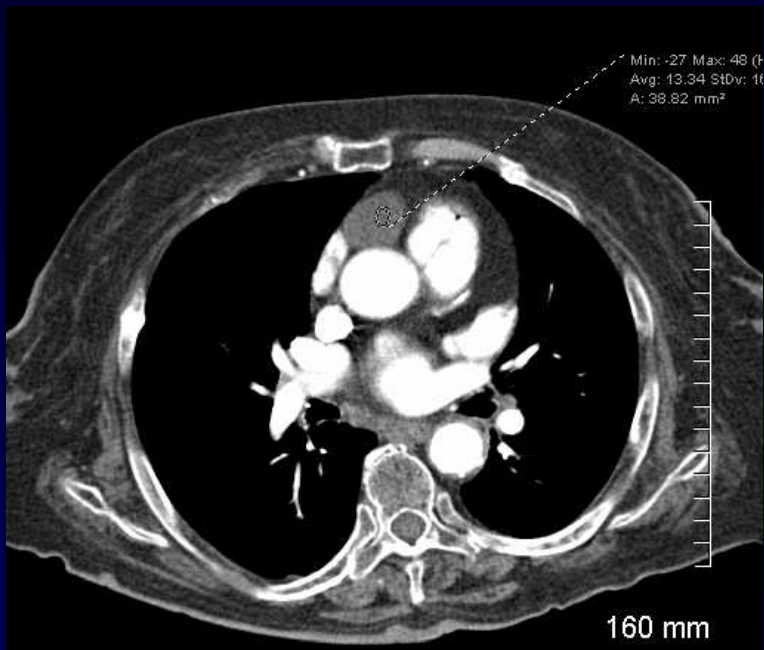
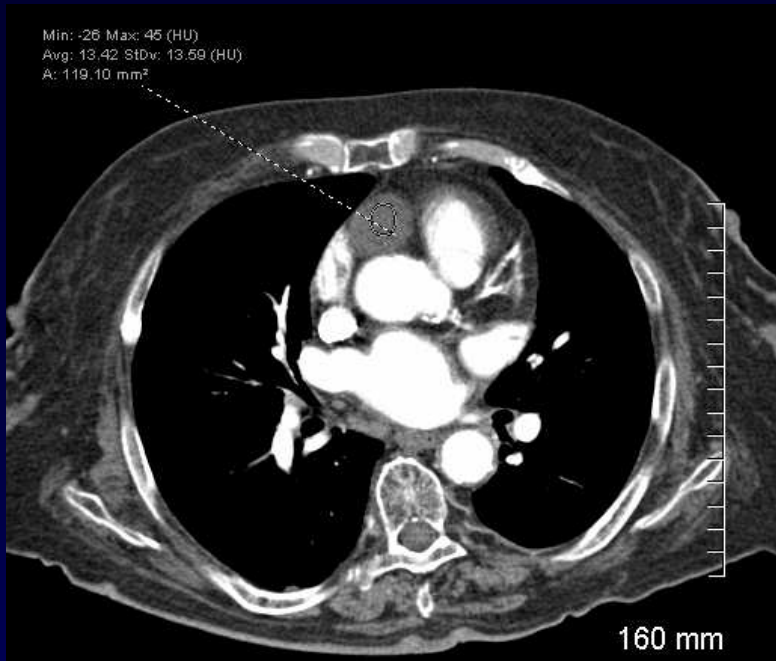

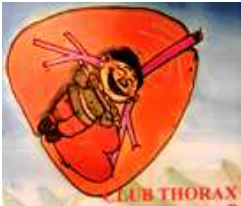
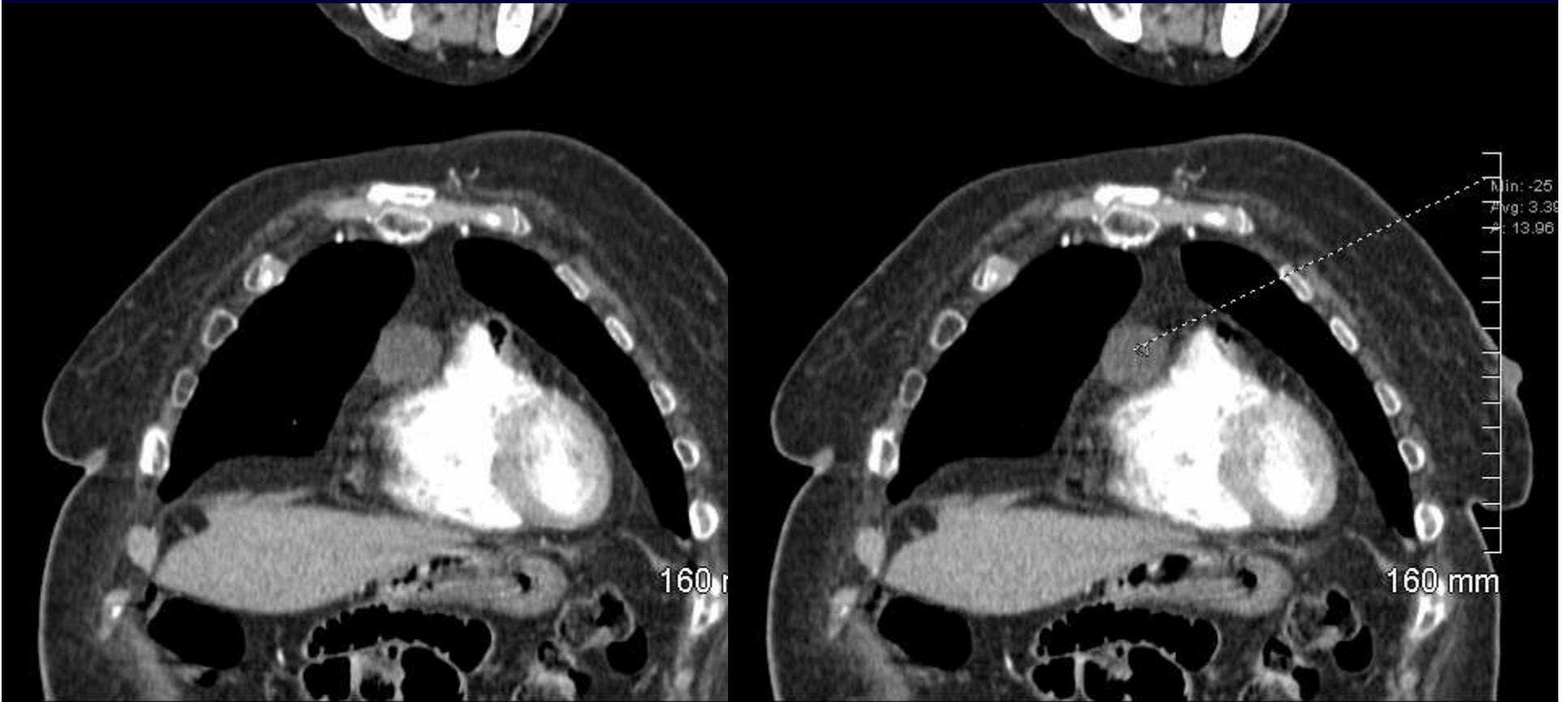
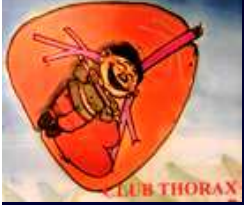**J GIRON – P FAJADET**

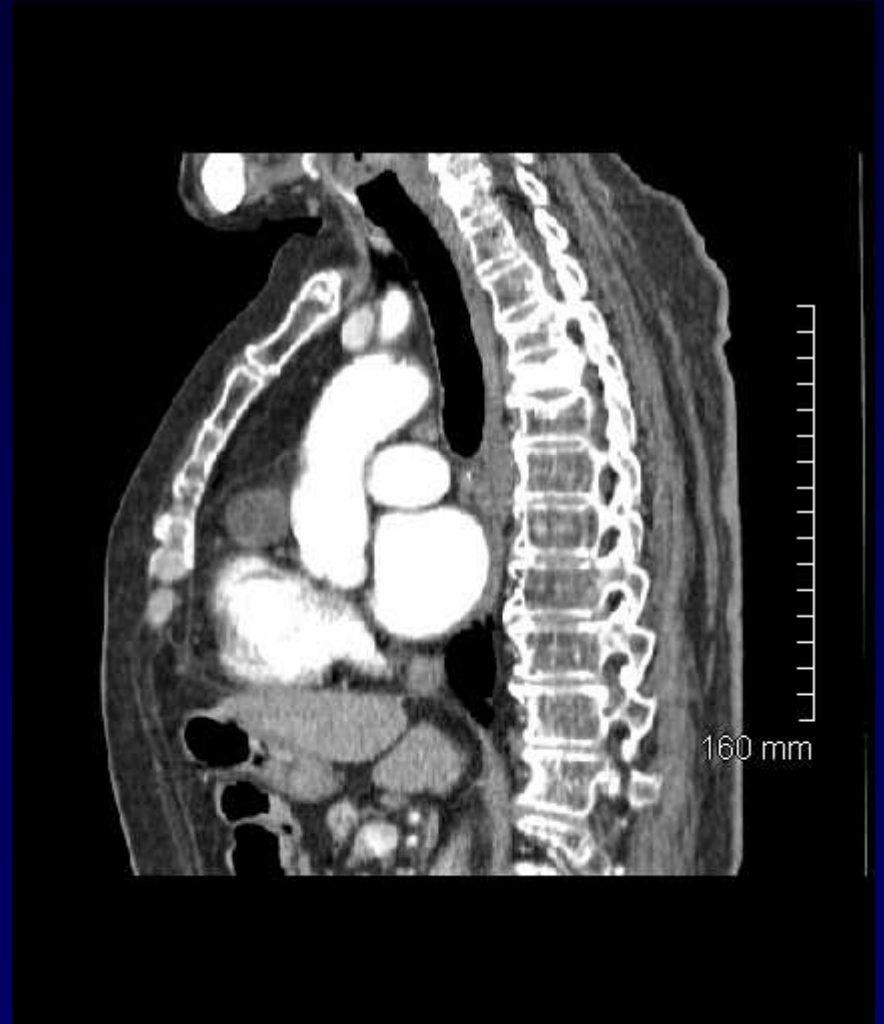
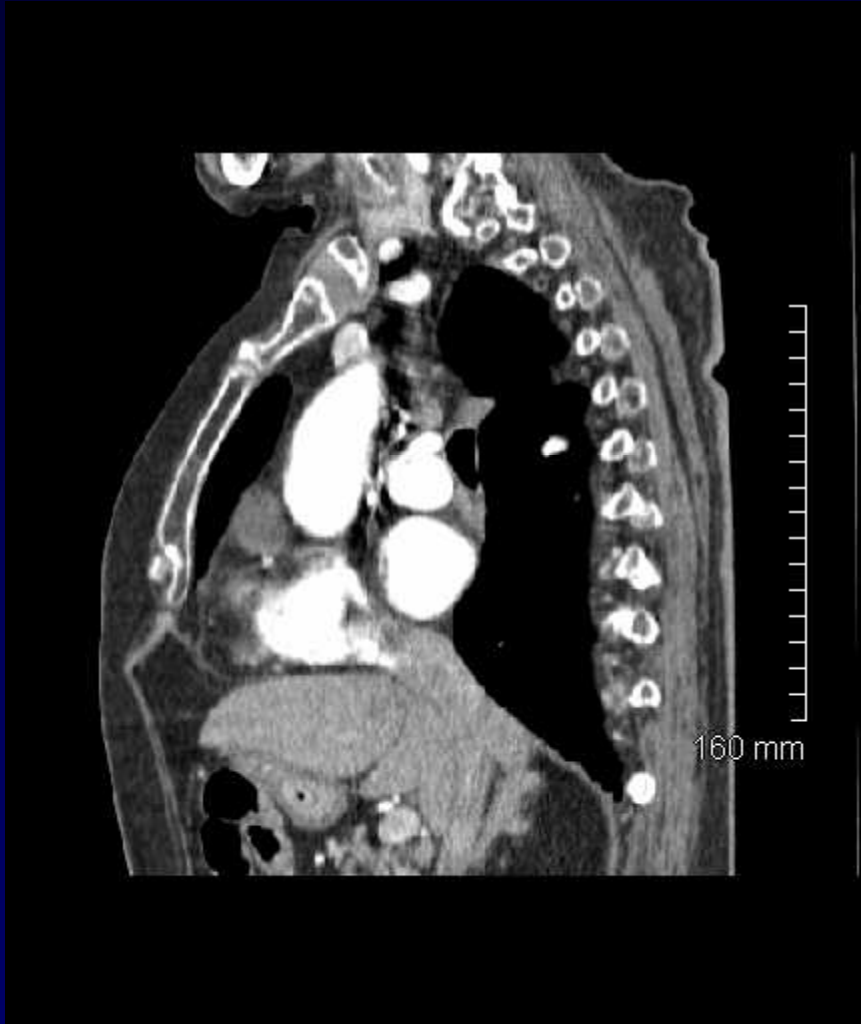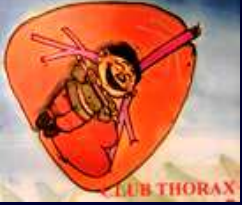Femme de 55 ans

**DECOUVERTE FORTUITE**











**Diagnostic ?**



# VRAISEMBLABLE KYSTE PERICARDIQUE